REVIEW

Dopaminergic Pathway Imaging

A Visual and Educational Guide

Michal Pudis, Laura Rodríguez-Bel, Montserrat Cortés-Romera, and Marina Suárez-Piñera

Neurol Clin Pract. 2026;16:e200599. doi:10.1212/CPJ.0000000000200599

Correspondence
Dr. Pudis
michalpudis@gmail.com

Abstract

Purpose of Review

Dopaminergic molecular imaging has evolved from an esoteric research tool to an indispensable adjunct in the diagnosis, management, and teaching of movement and neuropsychiatric disorders. Despite its clinical relevance, many neurology trainees encounter dopamine transporter (DAT) SPECT, [18F]FDOPA PET, and emerging vesicular monoamine transporter-2 (VMAT2) tracers only sporadically and often without a cohesive interpretive framework. This narrative review aims to provide a visually driven, clinically grounded roadmap that links dopaminergic neurochemistry and pathway anatomy to in vivo molecular imaging, with a specific focus on education and bedside application.

Recent Findings

Advances in dopaminergic imaging now allow in vivo interrogation of dopamine synthesis, vesicular storage, synaptic reuptake, postsynaptic receptor signaling, and metabolism using complementary SPECT and PET radiotracers. Presynaptic techniques (FDOPA PET, VMAT2 PET, or DAT SPECT/PET) reliably detect nigrostriatal degeneration, clarify equivocal parkinsonian presentations, and highlight phenotypic variants, including genetic and drug-related mimics. Postsynaptic D_2/D_3 receptor imaging refines differentiation between neurodegenerative and drug-induced parkinsonism, whereas myocardial [123I]-MIBG scintigraphy adds autonomic context that strengthens separation of synucleinopathies from tauopathies. Educational strategies increasingly emphasize pathway-based interpretation, recognition of common pitfalls (such as false-negative DAT scans), and the integration of semiquantitative metrics. Emerging machine learning approaches and standardized quantification pipelines are improving reproducibility and scalability across centers.

Summary

By integrating dopaminergic pathway anatomy, molecular neurotransmission, and tracer-specific imaging patterns, dopaminergic scans can be transformed from isolated diagnostic tests into powerful clinical and educational tools. A visually anchored, circuit-based teaching approach—supported by schematic figures, comparative tables, and case-based discussion—enhances trainee understanding and clinical confidence. This guide aims to equip neurologists and trainees with a coherent framework for deploying dopaminergic imaging effectively at the bedside and in the classroom, while preparing the field for quantitative and theragnostic advances.

Introduction

Dopamine functions as the molecular currency that translates motivation into movement, cognition, and reward. When dopaminergic transmission fails—due to neuronal loss, synaptic dysfunction, or pharmacologic blockade—the resulting clinical spectrum extends from bradykinesia and rigidity to psychosis and addiction. Parkinson disease (PD) and related parkinsonian syndromes exemplify the profound impact of dopaminergic imbalance on human behavior and neurologic function.[1]

From the Nuclear Medicine - PET (IDI), Bellvitge University Hospital - IDIBELL, L'Hospitalet de Llobregat, Barcelona, Spain.

Copyright © 2026 American Academy of Neurology

Copyright © 2026 American Academy of Neurology. Unauthorized reproduction of this article is prohibited.

Downloaded from https://www.neurology.org by Cardiff University (cfu) / Wales on 14 March 2026

Over the past 3 decades, molecular imaging has become a cornerstone in the evaluation of dopaminergic disorders. Since the introduction of ^{123}I-FP-CIT (DaTSCAN) SPECT in the 1990s, the tracer landscape has expanded to include ^{18}F-FDOPA PET for assessing dopamine synthesis, VMAT2 PET for vesicular storage, and postsynaptic receptor ligands for mapping D_2/D_3 receptor availability.[2,3] These imaging tools enable clinicians to visualize, quantify, and monitor the integrity of the nigrostriatal and mesolimbic pathways, effectively bridging neuropathologic mechanisms with bedside evaluation.[4]

Consensus and practice documents from the Society of Nuclear Medicine and Molecular Imaging (SNMMI) and the European Association of Nuclear Medicine (EANM)—including the 2020 EANM/SNMMI guideline for dopaminergic imaging—have standardized acquisition protocols, interpretation criteria, and tracer selection algorithms.[5] These efforts have strengthened the reproducibility and clinical relevance of dopaminergic imaging. Nevertheless, surveys of residency curricula and clinical practice reveal ongoing gaps in education and confidence regarding the selection and interpretation of these studies.[6] Many neurologists remain uncertain about how to integrate molecular imaging into patient management, particularly in conditions such as dementia with Lewy bodies (DLB), drug-induced parkinsonism, and atypical parkinsonian syndromes.[7,8]

This educational review aims to address those gaps. It offers a visual and pedagogical roadmap for clinicians and trainees to interpret and teach dopaminergic imaging effectively. The article integrates neuroanatomical and molecular foundations with case-based interpretation and practical teaching strategies. By focusing on clinically available modalities—DaTSCAN and ^{18}F-FDOPA PET—and introducing complementary research tools such as VMAT2 PET, this review emphasizes how each tracer answers specific biological questions. The ultimate objective is to help neurologists translate molecular images into meaningful clinical insights, standardize reporting, and prepare the next generation of practitioners for precision neurology.

Dopaminergic Pathways in the Human Brain

Fewer than half a million dopamine-synthesizing neurons are distributed mainly within the ventral tegmental area (VTA) and the substantia nigra pars compacta (SNc). These neurons give rise to 4 principal dopaminergic circuits—nigrostriatal, mesolimbic, mesocortical, and tuberoinfundibular—that collectively form the neurochemical framework governing movement, motivation, cognition, and neuroendocrine regulation.

An educational overview of these 4 core pathways is summarized in Table 1, whereas their anatomic trajectories and relative targets are illustrated in Figure 1. These visual aids help trainees conceptualize how dopaminergic signaling integrates across cortical, limbic, and subcortical structures. Together, these circuits form the foundation for interpreting clinical dopaminergic molecular imaging—particularly DaTSCAN and FDOPA PET—in the evaluation of parkinsonian syndromes, dementia with Lewy bodies, and other neuropsychiatric disorders.[9]

Nigrostriatal Pathway

The nigrostriatal pathway originates in the dorsolateral SNc and projects to the posterior putamen and dorsal caudate nucleus. It regulates the amplitude and fluidity of voluntary movements through modulation of cortico-basal ganglia loops. Degeneration of this pathway produces the cardinal motor features of PD—bradykinesia, rigidity, and rest tremor. Molecular imaging with DaTSCAN or [18F]FDOPA PET reveals asymmetric loss of striatal uptake, often beginning in the contralateral posterior putamen. Visualizing this topography helps trainees understand how imaging correlates directly with clinical laterality and disease severity.[9]

Mesolimbic Pathway

The mesolimbic pathway arises from the VTA and projects to the nucleus accumbens, amygdala, and hippocampus. It mediates the brain's reward and reinforcement mechanisms, linking dopaminergic signaling to pleasure, motivation, and addiction. Dysregulation of this circuit contributes to impulse control disorders, addiction, and psychosis. In schizophrenia, for example, FDOPA PET demonstrates elevated presynaptic dopamine synthesis in the striatum, supporting the hyperdopaminergic hypothesis.[10] Clinicians should appreciate how dopaminergic overactivity here can manifest as hallucinations or euphoria—symptoms sometimes observed in patients with PD under dopaminergic therapy.

Mesocortical Pathway

The mesocortical pathway extends from the VTA to the dorsolateral prefrontal cortex and anterior cingulate gyrus, modulating executive function, working memory, and cognitive flexibility. Hypofunction of this pathway contributes to apathy, bradyphrenia, and executive dysfunction in both PD and schizophrenia. In imaging studies, cortical FDOPA or receptor PET may show reduced dopaminergic tone correlating with cognitive decline. Understanding this dissociation between motor and cognitive dopaminergic deficits is vital for comprehensive interpretation of neurodegenerative and psychiatric disorders.[10]

Tuberoinfundibular Pathway

The tuberoinfundibular pathway connects the hypothalamic arcuate nucleus to the pituitary gland through the median eminence, where dopamine acts as the primary inhibitory regulator of prolactin secretion. Antipsychotic drugs that block D_2 receptors may interfere with this negative feedback, resulting in hyperprolactinemia and endocrine dysfunction. Imaging with high-affinity D_2/D_3 ligands such as [^{123}I]-IBZM, [^{11}C]-

Downloaded from https://www.neurology.org by Cardiff University (cfu) / Wales on 14 March 2026

Copyright © 2026 American Academy of Neurology. Unauthorized reproduction of this article is prohibited.

Table 1 Simplified Dopaminergic Pathway Overview

Pathway	Origin → primary target	Core function
Nigrostriatal	SNc → posterior putamen	Motor execution & scaling
Mesolimbic	VTA → nucleus accumbens	Reward & motivation
Mesocortical	VTA → prefrontal cortex	Executive control
Tuberoinfundibular	Arcuate nucleus → median eminence	Prolactin regulation

raclopride, or [^{18}F]-fallypride can quantify receptor occupancy and monitor pharmacodynamic effects in vivo, offering an educational example of how molecular imaging bridges neuroendocrinology and psychopharmacology.[11]

Retinodopaminergic Pathway

In the retina, dopamine is synthesized by a population of amacrine and interplexiform cells that regulate visual adaptation, photoreceptor coupling, and circadian rhythm. Although direct retinal PET imaging remains experimental, early research using FDOPA PET and electroretinography suggests reduced dopaminergic tone in carriers of LRRK2 and GBA variations—years before the onset of PD symptoms. This highlights the potential of peripheral dopaminergic biomarkers for identifying prodromal neurodegeneration.[12]

Diencephalospinal Pathway (A11 System)

The A11 dopaminergic system, originating in the posterior hypothalamus, provides the only known dopaminergic projection to the spinal cord. It modulates nociceptive transmission and autonomic control, influencing conditions such as restless leg syndrome, pain syndromes, and multiple system atrophy (MSA). Although not routinely visualized clinically, VMAT2 PET and autoradiographic data reveal selective A11 neuron loss in MSA, underscoring its translational importance for future radiotracer development.[13]

Each dopaminergic pathway supports a distinct functional domain and exhibits characteristic imaging correlates. The nigrostriatal system explains parkinsonian motor symptoms; mesolimbic and mesocortical networks relate to behavior, mood,

Figure 1 Major Dopaminergic Pathways in the Human Brain

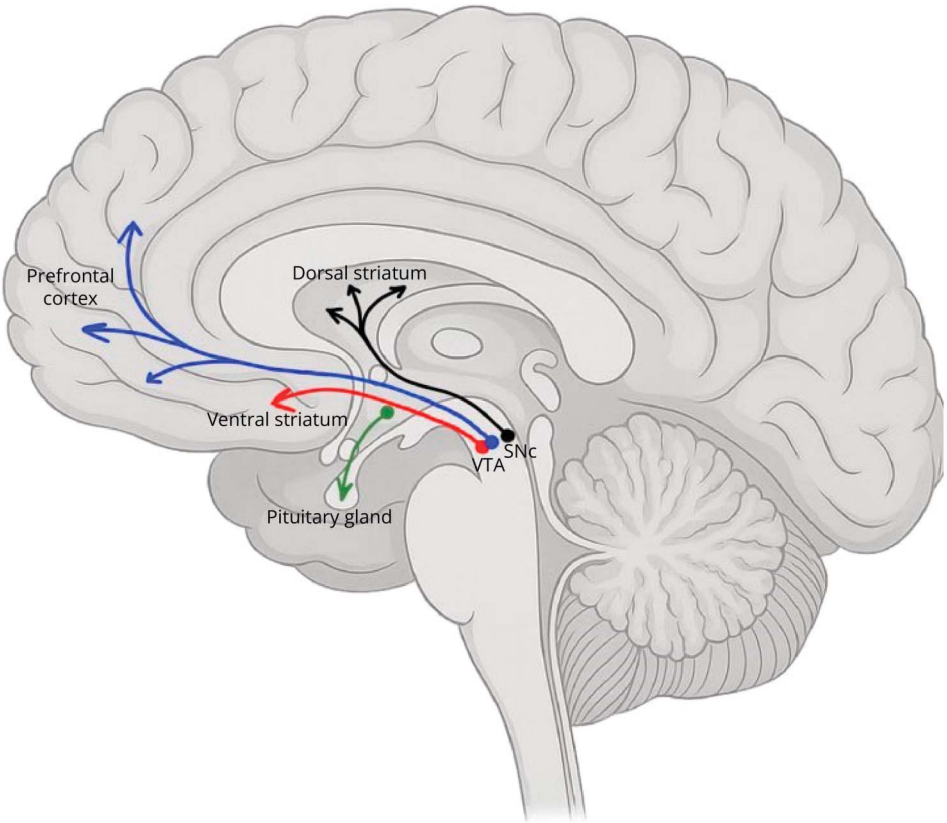

Diagram illustrating the 4 principal dopaminergic circuits: mesocortical (blue), mesolimbic (red), nigrostriatal (black), and tuberoinfundibular (green). SN = substantia nigra; VTA = ventral tegmental area.

Downloaded from https://www.neurology.org by Cardiff University (cfu) / Wales on 14 March 2026

Copyright © 2026 American Academy of Neurology. Unauthorized reproduction of this article is prohibited.

and cognition; and tuberoinfundibular and retinodopaminergic circuits emphasize dopaminergic control beyond movement. Teaching trainees to associate these circuits with specific imaging abnormalities fosters deeper conceptual understanding. Integrating pathway anatomy with tracer physiology enables neurologists to interpret molecular images as functional maps—linking neurochemistry to clinical presentation.

Molecular Basis of Dopaminergic Neurotransmission

Dopaminergic neurotransmission relies on a complex interplay of synthesis, vesicular storage, synaptic release, receptor binding, and reuptake. Understanding these molecular steps is essential for interpreting how radiotracers visualize different aspects of the dopaminergic system in vivo. The primary components of this process—dopamine synthesis, vesicular packaging, synaptic signaling, and reuptake—each provide distinct targets for molecular imaging and pharmacologic modulation. An overview of these key molecular targets is presented in Table 2, whereas Figure 2 provides a diagram illustrating the sequential enzymatic steps of dopamine synthesis, serving as a visual reference for learners and clinicians.[14]

Dopamine Synthesis

Dopamine is synthesized in the cytoplasm of presynaptic neurons through a two-step enzymatic process. The rate-limiting enzyme tyrosine hydroxylase (TH) converts the amino acid tyrosine to L-3,4-dihydroxyphenylalanine (L-DOPA), which is then decarboxylated by aromatic-L-amino acid decarboxylase (AADC) to produce dopamine. The activity of AADC forms the molecular basis for imaging with [^{18}F]FDOPA PET, which reflects presynaptic dopamine synthesis capacity.[15] This step is particularly relevant in early Parkinson disease, where compensatory upregulation of AADC may temporarily preserve dopaminergic tone despite axonal degeneration.[16]

Vesicular Storage and Synaptic Release

Once synthesized, dopamine is transported into synaptic vesicles by the vesicular monoamine transporter type 2 (VMAT2). Vesicular sequestration prevents oxidative degradation of dopamine and primes it for activity-dependent release. PET tracers such as [^{18}F]AV-133 (DTBZ) and [^{11}C]dihydrotetrabenazine allow in vivo quantification of VMAT2 density, serving as markers of presynaptic terminal integrity.[17] These ligands have proven valuable for distinguishing degenerative from nondegenerative parkinsonian syndromes and for studying disorders such as Huntington disease and multiple system atrophy.

Table 2 Key Molecular Targets in Dopaminergic Neurotransmission

Step	Molecular target	Representative tracer
Synthesis	AADC	^{18}F-FDOPA
Vesicular storage	VMAT2	^{18}F-FP-(+)-DTBZ
Reuptake	DAT	^{123}I-FP-CIT (DaTSCAN)
Postsynaptic receptors	D_2/D_3	^{123}I-IBZM/^{18}F-Fallypride

Figure 2 Molecular Basis of Dopamine Neurotransmission

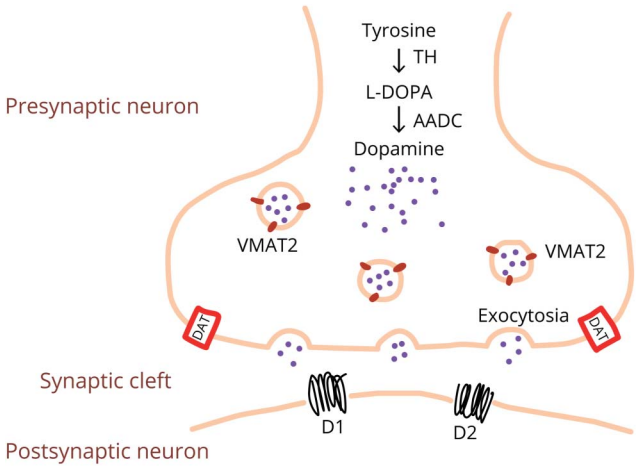

Diagram showing dopamine synthesis (from tyrosine through tyrosine hydroxylase [TH] to L-DOPA, and through aromatic-L-amino-acid decarboxylase [AADC] to dopamine), followed by vesicular storage using VMAT2, synaptic release, postsynaptic receptor binding (D_1 and D_2), and reuptake using dopamine transporter (DAT).

Dopamine Release, Binding, and Signal Transduction

On depolarization, vesicular dopamine is released into the synaptic cleft, where it binds to dopamine receptors classified into D_1-like (D_1, D_5) and D_2-like (D_2, D_3, D_4) families. D_1-like receptors are coupled to Gs proteins, stimulating cyclic AMP production, whereas D_2-like receptors are coupled to Gi proteins, inhibiting adenylate cyclase and reducing intracellular signaling.[18] Radiotracers such as [^{11}C]raclopride or [^{18}F]fallypride bind to postsynaptic D_2/D_3 receptors, enabling visualization of receptor availability and occupancy by pharmacologic agents.[19] Changes in binding potential can indicate alterations in receptor density or competition with endogenous dopamine release, as observed in reward paradigms and drug response studies.

Dopamine Reuptake and Degradation

After synaptic transmission, dopamine is cleared primarily through the dopamine transporter (DAT), which recycles dopamine into presynaptic terminals. The transporter's density correlates with the number of functional dopaminergic neurons, making it a key biomarker for imaging with [^{123}I]FP-CIT (DaTSCAN) or [^{18}F]FE-PE2I PET.[20] Once internalized, dopamine is metabolized by monoamine oxidase and catechol-O-methyltransferase to produce homovanillic acid, which can be measured in CSF or plasma as an indirect marker of dopaminergic turnover.[21]

Downloaded from https://www.neurology.org by Cardiff University (cfu) / Wales on 14 March 2026

Copyright © 2026 American Academy of Neurology. Unauthorized reproduction of this article is prohibited.

Integration of Molecular Steps in Imaging

Each molecular target—AADC, VMAT2, DAT, and dopamine receptors—represents a distinct node of dopaminergic neurotransmission that can be visualized with specific radiotracers. By integrating these imaging biomarkers, clinicians can infer the functional status of dopaminergic neurons across disease stages. In Parkinson disease, for instance, DAT SPECT and VMAT2 PET measure presynaptic terminal integrity, FDOPA PET assesses enzymatic synthesis, and receptor PET (e.g., [^{11}C]raclopride) evaluates postsynaptic regulation.[22] Together, these complementary modalities provide a multidimensional framework for understanding both physiologic function and pathophysiologic disruption within dopaminergic circuits.

Presynaptic Dopaminergic Imaging

Presynaptic dopaminergic imaging is the cornerstone of functional neuroimaging in movement disorders, offering a window into the integrity and function of nigrostriatal terminals. By evaluating dopaminergic synthesis, vesicular storage, and transporter availability, these techniques provide an objective biomarker of neurodegeneration. The most clinically established modalities—[^{123}I]FP-CIT SPECT (DaTSCAN) and [^{18}F]FDOPA PET—play complementary roles. Although DaTSCAN remains the most widely used clinical test, FDOPA PET offers unique quantitative and anatomical advantages that are increasingly relevant for both diagnosis and education in neurology.[23]

Dopamine Transporter Imaging (DAT SPECT and PET)

DAT imaging reflects the density of dopamine transporters located on presynaptic terminals in the striatum, serving as a reliable marker of dopaminergic neuron integrity. The radiotracer [^{123}I]FP-CIT (DaTSCAN) is FDA-approved and EMA-approved for differentiating degenerative parkinsonian syndromes from nondegenerative causes such as essential tremor or drug-induced parkinsonism.[24] Imaging patterns typically reveal asymmetric loss of uptake, beginning in the contralateral posterior putamen, progressing anteriorly and toward the caudate as disease advances.

Quantitative PET alternatives, such as [^{18}F]FE-PE2I and [^{11}C]PE2I, provide higher spatial resolution and improved kinetic modeling, allowing precise quantification of DAT binding potential.[25] However, these PET tracers are not yet widely incorporated into routine clinical practice and are primarily used in specialized or research settings.

For clinicians, understanding the limitations of DAT imaging is equally important. Uptake can be influenced by medications that interact with the dopamine transporter or by comorbidities such as cerebrovascular lesions or dementia with Lewy bodies (DLB).[26] A summary of pharmacologic agents known to interfere with DaTSCAN interpretation is provided in Table 3, which serves as a practical reference when preparing patients for imaging. Furthermore, although DAT loss confirms nigrostriatal degeneration, it does not distinguish among PD, MSA, or progressive supranuclear palsy (PSP). In such contexts, integration with FDOPA PET or VMAT2 PET provides valuable complementary information.

Beyond parkinsonian syndromes, DAT imaging has become a cornerstone in the differential diagnosis of neurocognitive disorders with suspected dopaminergic degeneration. Among these, DLB is the prototypical synucleinopathy characterized by fluctuating cognition, visual hallucinations, REM sleep behavior disorder, and varying degrees of parkinsonism. Because cortical atrophy and metabolic changes may be nonspecific in early stages, DAT SPECT provides a direct neurochemical marker of presynaptic loss, complementing structural and metabolic imaging.

In DLB, [^{123}I]FP-CIT SPECT typically demonstrates bilateral, often symmetric reduction of striatal uptake, affecting both putamen and caudate nuclei. This contrasts with idiopathic PD, in which uptake loss is classically asymmetric and posterior-predominant, beginning in the contralateral putamen and advancing anteriorly and medially with disease progression. When cognitive symptoms appear before or within 1 year of motor onset, such diffuse striatal loss strongly supports a DLB diagnosis. Quantitatively, mean striatal binding ratios are reduced by approximately 20–40% compared with age-matched controls, correlating with attentional and visuospatial deficits. Conversely, normal DAT binding effectively rules out DLB and strongly favors Alzheimer disease (AD) or vascular cognitive impairment.[27]

It is important to note that DAT imaging is now recognized as a core supportive biomarker in the revised consensus diagnostic criteria for DLB[28] and is endorsed by both the FDA and EMA for this indication. The combination of DAT SPECT with [^{18}F]FDG PET, which typically reveals occipital hypometabolism and the "cingulate island sign," achieves diagnostic specificities above 90%. Similarly, myocardial [^{123}I]MIBG scintigraphy, which demonstrates cardiac sympathetic denervation, provides complementary confirmation of synucleinopathy and further differentiates DLB and PD from MSA and PSP.[29]

Representative visual and quantitative analysis (DaTQUANT) is illustrated in Figure 3. Beyond qualitative interpretation, DaTQUANT software enables semiautomated quantification of striatal uptake and comparison against age-matched normative databases, generating Z-scores that objectify visual findings and facilitate cross-scanner standardization. This quantitative approach is particularly valuable for training and for borderline or symmetric cases, where visual asymmetry alone may underestimate early or diffuse dopaminergic loss.

Downloaded from https://www.neurology.org by Cardiff University (cfu) / Wales on 14 March 2026

Copyright © 2026 American Academy of Neurology. Unauthorized reproduction of this article is prohibited.

Table 3 Medications That May Affect DaTSCAN Imaging

Category	Examples	Potential effect
Antidepressants	Bupropion, SSRIs (e.g., sertraline, paroxetine, and fluoxetine)	May slightly reduce tracer binding
Psychostimulants/ADHD drugs	Methylphenidate, dexamfetamine	Lower apparent DAT uptake
Appetite suppressants	Phentermine, amphetamine derivatives	Decrease uptake in striatum
Wake-promoting agents	Modafinil	Mild reduction possible
Illicit substances	Cocaine	Strong competition for DAT; marked reduction

Note: These agents can alter DAT binding and potentially lead to false-positive or ambiguous findings. When feasible, temporary discontinuation before DaTSCAN is advised.

[18F]FDOPA PET: Dopamine Synthesis Capacity

[^{18}F]FDOPA PET quantifies presynaptic dopamine synthesis by measuring the activity of aromatic-L-amino-acid decarboxylase (AADC), the enzyme responsible for converting L-DOPA into dopamine.[30] This approach provides a direct and reliable index of dopaminergic biosynthetic capacity and complements dopamine-transporter (DAT) imaging by assessing a different step in the presynaptic pathway (Table 4 presents a comparative overview). Although DaTSCAN reflects axon terminal density, FDOPA PET visualizes enzymatic function, offering a more dynamic perspective on residual dopaminergic capacity across both motor and nonmotor networks.

In PD, FDOPA PET typically demonstrates a posterior-to-anterior gradient of striatal loss, with the most pronounced

Figure 3 Comparative DaTSCAN Patterns in Parkinson Disease (PD) and Dementia With Lewy Bodies (DLB)

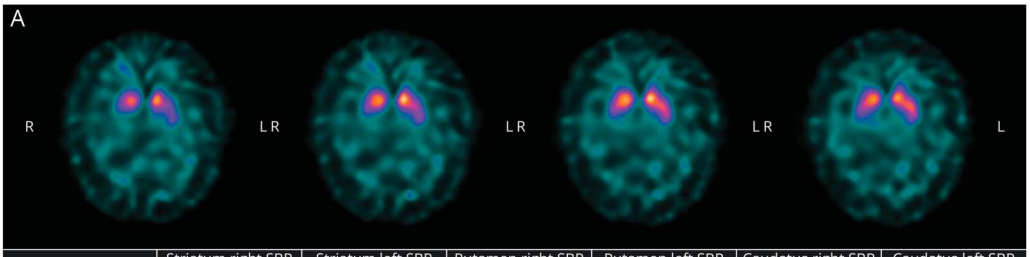

	Striatum right SBR	Striatum left SBR	Putamen right SBR	Putamen left SBR	Caudatus right SBR	Caudatus left SBR
Measured	+2.32	+2.62	+2.00	+2.34	+3.05	+3.16
Mean (±1 SD)	+2.91 (±0.35)	+2.69 (±0.37)	+2.62 (±0.31)	+2.43 (±0.36)	+3.57 (±0.65)	+3.19 (±0.53)
Deviation	–20%	–3%	–24%	–4%	–14%	–1%
Z-score	–1.66	–0.20	–2.00	–0.26	–0.79	–0.06

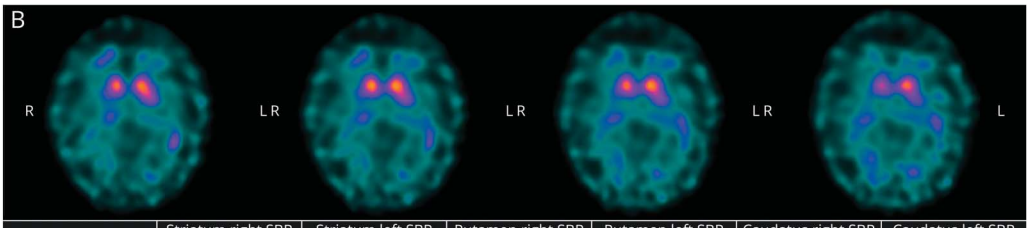

	Striatum right SBR	Striatum left SBR	Putamen right SBR	Putamen left SBR	Caudatus right SBR	Caudatus left SBR
Measured	+0.91	+1.28	+0.62	+1.01	+1.57	+1.82
Mean (±1 SD)	+2.90 (±0.35)	+2.87 (±0.37)	+2.62 (±0.31)	+2.50 (±0.36)	+3.78 (±0.65)	+3.59 (±0.53)
Deviation	–69%	–55%	–75%	–59%	–59%	–49%
Z-score	–5.63	–4.23	–6.15	–4.14	–3.40	–3.33

Axial [^{123}I]FP-CIT SPECT images illustrating 2 simulated educational cases analyzed with DaTQUANT. (A) Early Parkinson disease in a patient presenting with tremor of the left hand. Asymmetric reduction of uptake is evident in the right posterior putamen, with preserved caudate activity—producing the classic "comma-to-dot" pattern. Quantitative analysis confirms reduced binding in the right putamen (Z = −2). (B) Dementia with Lewy bodies evaluated for differential diagnosis with Alzheimer disease. Uptake is globally and symmetrically reduced across the putamen and caudate, with blurred striatal margins and elevated background activity. Quantitative comparison with the normative database reveals generalized presynaptic loss (right striatum −5.63, left striatum −4.23). Simulated educational cases; no real patient data are shown.

Downloaded from https://www.neurology.org by Cardiff University (cfu) / Wales on 14 March 2026

Copyright © 2026 American Academy of Neurology. Unauthorized reproduction of this article is prohibited.

Table 4 Comparison Between DaTSCAN and [^{18}F]FDOPA PET

Feature	DaTSCAN	[^{18}F]FDOPA PET	Key teaching point
Biologic target	Dopamine transporter (DAT) on presynaptic terminals	Aromatic-L-amino-acid decarboxylase (AADC) in dopaminergic neurons	DAT = axon integrity · FDOPA = enzymatic function
Primary measurement	Striatal binding ratio (SBR) or Z-score vs normal database	Influx constant (K□) or standardized uptake value ratio (SUVr)	Both quantify presynaptic integrity but at distinct molecular steps
Sensitivity and specificity	High specificity for presynaptic degeneration but prone to false positives from drugs with DAT affinity (e.g., bupropion and methylphenidate)	High sensitivity and quantitative reproducibility, but may miss very early compensatory stages	Understanding each tracer's limitations avoids overdiagnosis or underdiagnosis
Clinical availability	Widely available; FDA/EMA-approved for PD vs ET and DLB	Restricted to PET centers; EANM-endorsed alternative when available	DaTSCAN for routine diagnosis; FDOPA PET for advanced or research use

reduction in the contralateral posterior putamen (Figure 4).[27] In early or prodromal PD, compensatory AADC upregulation may transiently preserve FDOPA uptake despite ongoing axonal loss, explaining why some very early cases present with borderline or even normal scans.[31] Because of its quantitative nature, FDOPA PET is particularly suited for longitudinal monitoring and for exploring dopaminergic function in cortical and limbic circuits, regions beyond the spatial resolution and kinetic reach of SPECT tracers.

From an educational perspective, FDOPA PET provides neurologists and trainees with a powerful visual framework linking anatomy to symptomatology—posterior putaminal loss correlating with bradykinesia and rigidity, and reduced prefrontal or limbic uptake correlating with cognitive or affective symptoms. Modern hybrid PET/MRI systems enhance this teaching value by delivering high-resolution structural, diffusion, and metabolic data within a single session, improving both anatomical localization and quantitative reliability.[32]

Advances in automated kinetic modeling—such as Logan graphical analysis—and machine learning-based segmentation have further improved reproducibility, reduced observer variability, and facilitated multicenter harmonization.[33] These developments have made FDOPA PET not only a research instrument but also a practical clinical biomarker capable of tracking disease progression and therapeutic response.

Clinically, FDOPA PET is useful across a broad spectrum of disorders that affect dopaminergic synthesis. In Parkinson disease, it delineates striatal involvement and enables objective follow-up. In atypical parkinsonian syndromes and dopa-responsive dystonia, it helps clarify disease mechanism and guide treatment. In neurodegenerative dementias, particularly dementia with Lewy bodies (DLB), reduced putaminal FDOPA uptake may precede cortical hypometabolism, providing an early marker of synucleinopathy.[34] The European Association of Nuclear Medicine (EANM) recognizes FDOPA PET as a valid alternative to DAT SPECT in centers where available—especially in patients with atypical clinical features or inconclusive DaTSCAN findings.[5]

VMAT2 PET: Vesicular Storage Integrity

The vesicular monoamine transporter type 2 (VMAT2) facilitates dopamine storage within presynaptic vesicles, protecting neurons from cytosolic accumulation and

Figure 4 [18F]FDOPA PET in Parkinson Disease

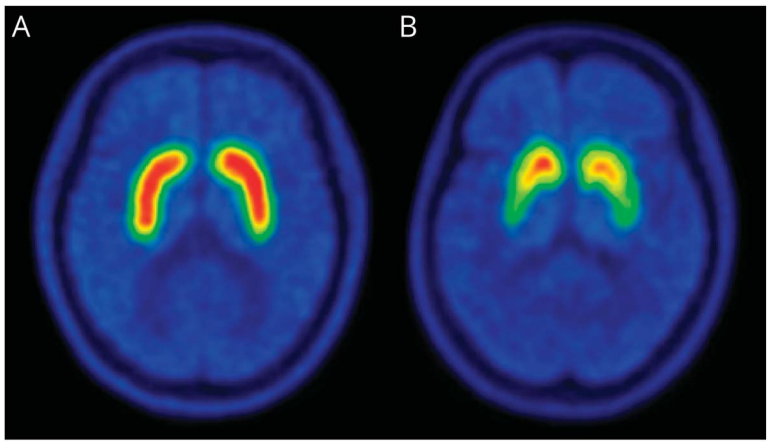

(A) Physiologic [^{18}F]FDOPA uptake in a healthy individual showing symmetric, homogeneous activity in both putamen and caudate nuclei. (B) Parkinson disease case demonstrating decreased [^{18}F]FDOPA uptake in both putamina, predominantly on the left side, consistent with contralateral motor symptoms. The posterior-to-anterior gradient of dopaminergic loss is evident, whereas caudate activity is relatively preserved. Simulated educational cases; no real patient data are shown. Note: [^{18}F]FDOPA PET provides higher spatial resolution and image quality than SPECT-based tracers, allowing clearer delineation of striatal subregions and cortical structures, which enhances both clinical interpretation and teaching value.

Downloaded from https://www.neurology.org by Cardiff University (cfu) / Wales on 14 March 2026

Copyright © 2026 American Academy of Neurology. Unauthorized reproduction of this article is prohibited.

oxidative stress. PET tracers such as [^{18}F]AV-133 (DTBZ) and [^{11}C]dihydrotetrabenazine allow in vivo quantification of vesicular storage capacity, offering a direct marker of presynaptic terminal density independent of compensatory AADC upregulation.[35] VMAT2 binding correlates strongly with postmortem nigral neuron counts, providing a stable and reproducible index of dopaminergic integrity.[36]

Unlike DAT imaging, VMAT2 PET is largely unaffected by dopaminergic or antidepressant medications, making it highly suitable for longitudinal studies and drug-occupancy quantification (e.g., tetrabenazine and valbenazine). However, its limited clinical adoption reflects several barriers: the lack of regulatory approval for routine use, the short half-life of [^{11}C]-labeled tracers, the high production cost of [^{18}F] alternatives, and the absence of clear incremental benefit over widely available DAT SPECT in most clinical scenarios. At present, VMAT2 PET remains primarily a research and validation tool rather than a frontline diagnostic modality.

Comparative and Educational Considerations

All presynaptic imaging modalities probe dopaminergic neuron integrity but at different molecular checkpoints:

- [^{123}I]FP-CIT SPECT measures transporter density (DAT),
- [^{18}F]FDOPA PET quantifies enzymatic synthesis (AADC), and
- VMAT2 PET assesses vesicular storage stability.

Understanding these distinctions refines both diagnosis and teaching. For instance, a normal FDOPA PET with reduced VMAT2 suggests early axonal degeneration masked by enzymatic compensation, whereas an abnormal DAT SPECT with preserved VMAT2 may indicate drug interference rather than true neuronal loss.[20]

From an educational perspective, VMAT2 imaging completes the conceptual triad of dopaminergic integrity—synthesis, storage, and reuptake—providing a clear visual and biochemical framework for residents and trainees. When combined with postsynaptic receptor imaging, these modalities bridge neurochemistry with clinical syndromes, transforming dopaminergic imaging into an integrated, circuit-level learning model.

Postsynaptic Dopaminergic Imaging

Postsynaptic dopaminergic imaging evaluates the density and functional status of dopamine receptors—primarily D_2/D_3 receptors—in the striatum and other basal ganglia regions. These studies complement presynaptic imaging by revealing receptor-level adaptations that occur in response to dopaminergic neuron loss or pharmacologic modulation.[37]

Physiologic Basis and Receptor Regulation

Dopamine receptors are categorized into D_1-like (D_1, D_5) and D_2-like (D_2, D_3, D_4) families. The D_2/D_3 receptors, located predominantly on postsynaptic medium spiny neurons in the striatum, are the principal target of molecular imaging.[38] In PD, loss of dopaminergic input from the substantia nigra often leads to a compensatory upregulation of D_2 receptors in early disease stages, which may normalize or decline with chronic dopaminergic therapy or disease progression.[39] Conversely, atypical parkinsonian syndromes—such as MSA and PSP—demonstrate concurrent presynaptic and postsynaptic loss, producing more uniform reductions in both transporter and receptor binding.[40]

Radiotracers for D_2/D_3 Receptor Imaging

The most widely used SPECT radiotracer for postsynaptic imaging is [^{123}I]IBZM (iodobenzamide), which binds selectively to striatal D_2/D_3 receptors and allows assessment of receptor density.[41] Decreased uptake on IBZM SPECT indicates postsynaptic receptor loss, helping differentiate PD (where binding is typically preserved or increased) from atypical parkinsonian syndromes (where binding is reduced). PET analogs include [^{11}C]raclopride, [^{18}F]fallypride, and [^{11}C]FLB 457, which vary in affinity and cortical penetration.[42] Among these, [^{11}C]raclopride remains the reference standard for striatal D_2/D_3 receptor imaging because of its well-characterized kinetics and sensitivity to endogenous dopamine fluctuations.[43]

Clinical and Educational Applications

Postsynaptic imaging is particularly valuable in the differential diagnosis of parkinsonian syndromes. A normal or elevated D_2/D_3 receptor binding in the context of reduced presynaptic tracer uptake supports the diagnosis of PD, whereas concomitant loss of presynaptic and postsynaptic binding suggests an atypical parkinsonian disorder such as MSA or PSP.[44] In addition, receptor imaging plays an important role in neuropsychiatry, where it is used to quantify receptor occupancy by antipsychotic medications and to investigate dopamine-related disorders such as schizophrenia, addiction, and impulse control disorders.[45]

From an educational standpoint, the visual contrast between preserved and reduced D_2/D_3 receptor binding provides trainees with a clear demonstration of how dopaminergic degeneration patterns differ among parkinsonian syndromes. Representative examples are shown in Figure 5, which also highlights potential pharmacologic interference in postsynaptic imaging.

Adjunct Imaging: Myocardial MIBG Scintigraphy

Myocardial [^{123}I]-metaiodobenzylguanidine (MIBG) scintigraphy complements dopaminergic imaging by assessing cardiac sympathetic integrity, which parallels nigrostriatal degeneration in PD and DLB.[46] By contrast, MSA and PSP generally preserve myocardial innervation, helping to

Downloaded from https://www.neurology.org by Cardiff University (cfu) / Wales on 14 March 2026

Copyright © 2026 American Academy of Neurology. Unauthorized reproduction of this article is prohibited.

Figure 5 Drug Interference in Postsynaptic Dopamine Imaging

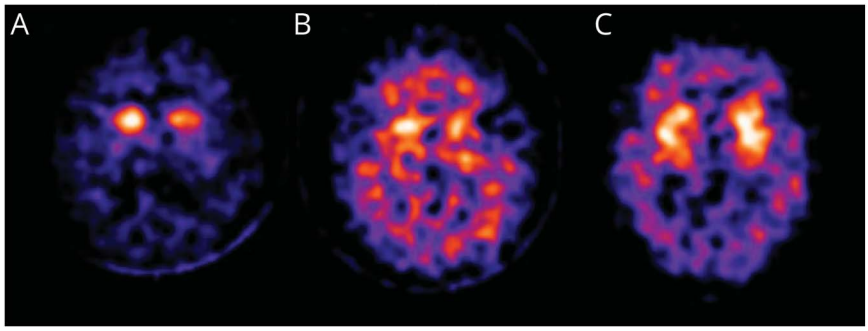

(A) DaTSCAN showing bilateral putaminal loss. (B) [^{123}I]IBZM SPECT acquired while on the D_2 agonist rotigotine demonstrates reduced postsynaptic binding. (C) Repeat IBZM performed 1 week after medication withdrawal shows normal striatal binding, confirming drug interference rather than true receptor loss. Simulated case for educational purposes; no real patient data are included. *Note: The lower spatial resolution of IBZM SPECT compared with DaTSCAN or FDOPA PET underscores the technological limitations of postsynaptic imaging. Presenting these side by side in teaching sessions reinforces the distinction between presynaptic and postsynaptic dysfunction.*

differentiate these conditions from synucleinopathies. Representative examples of normal and reduced myocardial uptake are illustrated in Figure 6, showing typical patterns seen in idiopathic Parkinson disease and dementia with Lewy bodies.

Physiologic Basis and Technique

Representative examples are shown in Figure 6, illustrating normal and abnormal myocardial MIBG uptake patterns for educational purposes. MIBG, a norepinephrine analog, is actively transported into sympathetic nerve terminals through the norepinephrine transporter (NET) and stored by VMAT2. Imaging is typically performed at 15–30 minutes (early) and 3–4 hours (delayed) after injection. The heart-to-mediastinum (H/M) ratio is the main quantitative measure; delayed H/M < 1.6 is considered abnormal.[29]

Clinical and Educational Value

Reduced myocardial MIBG uptake reflects postganglionic sympathetic denervation and supports a diagnosis of PD or DLB, whereas normal uptake suggests MSA or PSP.[47] Combining DaTSCAN or FDOPA PET with MIBG scintigraphy increases diagnostic confidence, particularly when presynaptic findings are inconclusive. For neurologists, MIBG imaging illustrates that PD and DLB extend beyond the brain, reinforcing their concept as multisystem synucleinopathies and serving as a concise educational tool alongside dopaminergic imaging.

Quantification and Image Analysis

Quantitative analysis in dopaminergic imaging provides an objective complement to visual interpretation, helping standardize evaluation across institutions and reduce interobserver variability. Although visual assessment remains the cornerstone of clinical reporting, semiquantitative tools enhance diagnostic confidence and are particularly useful for training and follow-up comparisons.[48]

Visual vs Quantitative Assessment

Visual interpretation continues to be the primary clinical method for reporting DaTSCAN and FDOPA PET studies. However, quantitative metrics—such as the specific binding ratio (SBR) or Z-score analysis—allow more precise

Figure 6 [123I]MIBG Scintigraphy in Parkinsonian Syndromes

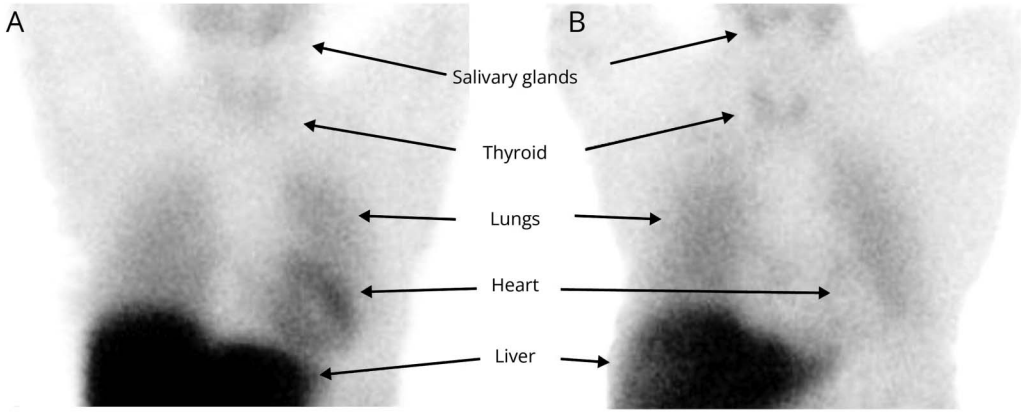

(A) Physiologic myocardial uptake. (B) Markedly reduced uptake, a pattern highly suggestive of idiopathic Parkinson disease or dementia with Lewy bodies. Simulated educational cases; no real patient data are shown.

Downloaded from https://www.neurology.org by Cardiff University (cfu) / Wales on 14 March 2026

Copyright © 2026 American Academy of Neurology. Unauthorized reproduction of this article is prohibited.

measurement of striatal tracer uptake relative to background activity.[49] Commercial and open-source software packages such as DaTQUANT, BRASS, or Neurocloud automatically calculate these ratios and display them alongside normative data, improving reproducibility and supporting longitudinal monitoring.

Quantitative assessment is particularly useful in borderline or asymmetric cases, where subtle differences in uptake may not be visually apparent. Nonetheless, quantification should always be interpreted in conjunction with visual analysis and clinical context, as technical factors (collimator type, reconstruction, and attenuation correction) can influence values.[5]

Educational and Clinical Value

For neurologists and trainees, quantitative imaging tools provide a visual bridge between anatomy, physiology, and clinical presentation. Comparing Z-score maps or SBR plots with symptom lateralization enhances understanding of striatal topography and disease progression. Incorporating quantitative analysis into teaching sessions also reinforces standardized reporting practices and highlights sources of technical variability.

Although quantitative analysis increases objectivity, expert interpretation remains essential—particularly in complex or early cases. A balanced approach that integrates both visual and quantitative findings represents best clinical and educational practice in dopaminergic imaging.

Conclusions

Dopaminergic molecular imaging has transformed the diagnostic approach to parkinsonian syndromes and related disorders by allowing clinicians to visualize, quantify, and understand the functional integrity of dopaminergic circuits in vivo. Beyond its diagnostic power, it has become an indispensable educational tool, bridging neuroanatomy, pathophysiology, and clinical neurology in a single image.

Presynaptic imaging, using DaTSCAN, FDOPA PET, or VMAT2 PET, remains the cornerstone for identifying nigrostriatal degeneration. DaTSCAN is the most accessible and standardized modality, whereas FDOPA PET offers superior spatial and quantitative insight, particularly for academic and training purposes. These techniques complement each other, guiding diagnostic decisions and deepening understanding of disease topography and progression.

Postsynaptic receptor imaging, through IBZM SPECT or D_2/D_3 PET, adds diagnostic specificity in complex or atypical cases. Demonstrating preserved or reduced receptor availability provides a functional distinction between idiopathic Parkinson disease and atypical parkinsonian syndromes such as MSA or PSP. Together, presynaptic and postsynaptic imaging form a coherent framework for teaching and clinical reasoning about dopaminergic dysfunction.

Adjunct imaging with ^{123}I-MIBG scintigraphy broadens this perspective by visualizing cardiac sympathetic integrity—an often-overlooked aspect of Lewy body diseases. Integrating MIBG with dopaminergic imaging reinforces the concept of Parkinson disease and dementia with Lewy bodies as multisystem neurodegenerative disorders.

Quantification brings further precision and reproducibility to interpretation. Semiautomated tools such as DaTQUANT and ENC-DAT standardize assessment and facilitate teaching by providing objective metrics to correlate imaging findings with clinical signs. Nonetheless, visual interpretation, guided by clinical context, remains central—emphasizing that technology should enhance, not replace, expert judgment.

From an educational standpoint, dopaminergic imaging represents an exemplary model for integrating neuroscience into clinical training. Its visual clarity helps trainee's link abstract pathophysiologic concepts to real-world patient manifestations, fostering deeper understanding and retention. As technology advances, hybrid PET/MRI and quantitative software will continue to enhance both the clinical and didactic value of these techniques.

In summary, dopaminergic imaging is more than a diagnostic tool—it is a pedagogical bridge between neurochemistry and clinical neurology. By combining presynaptic, postsynaptic, and adjunct imaging modalities within a simplified, clinically focused educational framework, neurologists and trainees can approach parkinsonian disorders with greater diagnostic precision, conceptual clarity, and confidence.

Author Contributions

M. Pudis: drafting/revision of the manuscript for content, including medical writing for content; major role in the acquisition of data; study concept or design; analysis or interpretation of data. L. Rodríguez-Bel: drafting/revision of the manuscript for content, including medical writing for content. M. Cortés-Romera: drafting/revision of the manuscript for content, including medical writing for content. M. Suarez-Piñera: drafting/revision of the manuscript for content, including medical writing for content.

Study Funding

The authors report no targeted funding.

Disclosure

The authors report no relevant disclosures. Full disclosure form information provided by the authors is available with the full text of this article at Neurology.org/cp.

Publication History

Received by *Neurology® Clinical Practice* July 24, 2025. Accepted in final form December 19, 2025. Submitted and externally peer-reviewed. The handling editor was Associate Editor John P. Ney, MD, MPH.

Downloaded from https://www.neurology.org by Cardiff University (cfu) / Wales on 14 March 2026

Copyright © 2026 American Academy of Neurology. Unauthorized reproduction of this article is prohibited.

References

1. Dorsey ER, Sherer T, Okun MS, Bloem BR. The emerging evidence of the Parkinson pandemic. *J Parkinsons Dis*. 2018;8(s1):S3–S8. doi:10.3233/JPD-181474
2. Arbizu J, Morbelli S, Minoshima S, et al. SNMMI procedure standard/EANM practice guideline for brain [18F]FDG PET imaging, version 2.0. *J Nucl Med*. 2025;66(suppl 2):S45–S60. doi:10.2967/jnumed.124.268754
3. Zhao R, Chen J, Ye T, et al. First-in-human study of D6-[18F]FP-(+)-DTBZ, a novel VMAT2 tracer: whole-body biodistribution and brain PET comparison with [18F]FP-(+)-DTBZ (AV-133). *EJNMMI Radiopharm Chem*. 2024;9(1):71. doi:10.1186/s41181-024-00301-y
4. Haber SN. Corticostriatal circuitry. *Dialogues Clin Neurosci*. 2016;18(1):7-21. doi:10.31887/DCNS.2016.18.1/shaber
5. Morbelli S, Esposito G, Arbizu J, et al. EANM practice guideline/SNMMI procedure standard for dopaminergic imaging in Parkinsonian syndromes 1.0. *Eur J Nucl Med Mol Imaging*. 2020;47(8):1885-1912. doi:10.1007/s00259-020-04817-8
6. Seibyl JP, Kuo P. What is the role of dopamine transporter imaging in parkinson prevention clinical trials? *Neurology*. 2022;99(7 suppl 1):61-67. doi:10.1212/WNL.0000000000200786
7. Bega D, Kuo PH, Chalkidou A, et al. Clinical utility of DaTscan in patients with suspected Parkinsonian syndrome: a systematic review and meta-analysis. *NPJ Parkinsons Dis*. 2021;7(1):43. doi:10.1038/s41531-021-00185-8
8. Di Luca DG, Perlmutter JS. Time for clinical dopamine transporter scans in parkinsonism?: not DAT yet. *Neurology*. 2024;102(11):e209558. doi:10.1212/WNL.0000000000209558
9. Björklund A, Dunnett SB. Dopamine neuron systems in the brain: an update. *Trends Neurosci*. 2007;30(5):194-202. doi:10.1016/j.tins.2007.03.006
10. Hart XM, Schmitz CN, Gründer G. Molecular imaging of dopamine partial agonists in humans. *Front Psychiatry*. 2022;13:832209. doi:10.3389/fpsyt.2022.832209
11. Laruelle M, D'Souza CD, Baldwin RM, et al. Imaging D2 receptor occupancy by endogenous dopamine in humans. *Neuropsychopharmacology*. 1997;17(3):162-174. doi:10.1016/S0893-133X(97)00043-2
12. Oda Y, Kanahara N, Iyo M. Alterations of dopamine D2 receptors and related mechanisms in schizophrenia: an overview. *Int J Mol Sci*. 2015;16(12):26228-26245. doi:10.3390/ijms161226228
13. Farde L, Wiesel F-A, Halldin C, Sedvall G, Sedvall G. Central D2-dopamine receptor occupancy in schizophrenic patients treated with antipsychotic drugs. *Arch Gen Psychiatry*. 1988;45(1):71-76. doi:10.1001/archpsyc.1988.01800250087012
14. Hornykiewicz O. Dopamine (3-hydroxytyramine) and brain function. *Pharmacol Rev*. 1966;18(2):925-964.
15. Cummings JL, Henchcliffe C, Schaier S, Simuni T, Waxman A, Kemp P. The role of dopaminergic imaging in patients with symptoms of dopaminergic system neurodegeneration. *Brain*. 2011;134(Pt 11):3146-3166. doi:10.1093/brain/awr177
16. Pavese N, Brooks DJ. Imaging neurodegeneration in Parkinson's disease. *Biochim Biophys Acta*. 2009;1792(7):722-729. doi:10.1016/j.bbadis.2008.10.003
17. Xu SS, Alexander PK, Lie Y, et al. Diagnostic accuracy of imaging brain vesicular monoamine transporter type 2 (VMAT2) in clinically uncertain parkinsonian syndrome (CUPS): a 3-year follow-up study in community patients. *BMJ Open*. 2018;8(11):e025533. doi:10.1136/bmjopen-2018-025533
18. Beaulieu JM, Gainetdinov RR. The physiology, signaling, and pharmacology of dopamine receptors. *Pharmacol Rev*. 2011;63(1):182-217. doi:10.1124/pr.110.002642
19. la Fougère C, Pöpperl G, Levin J, et al. The value of the dopamine D2/3 receptor ligand 18F-desmethoxyfallypride for the differentiation of idiopathic and non-idiopathic parkinsonian syndromes. *J Nucl Med*. 2010;51(4):581-587. doi:10.2967/jnumed.109.071811
20. Brooks DJ. Molecular imaging of dopamine transporters. *Ageing Res Rev*. 2016;30:114-121. doi:10.1016/j.arr.2015.12.009
21. Eisenhofer G, Kopin IJ, Goldstein DS. Catecholamine metabolism: a contemporary view with implications for physiology and medicine. *Pharmacol Rev*. 2004;56(3):331-349. doi:10.1124/pr.56.3.1
22. Wallert ED, van de Giessen E, Knol RJJ, Beudel M, de Bie RMA, Booij J. Imaging dopaminergic neurotransmission in neurodegenerative disorders. *J Nucl Med* 2022;63(suppl 1):27S–32S. doi:10.2967/jnumed.121.263197
23. Booij J, Knol RJ. SPECT imaging of the dopaminergic system in (premotor) Parkinson's disease. *Parkinsonism Relat Disord*. 2007;13(suppl 3):S425–S428. doi:10.1016/S1353-8020(08)70042-7
24. Catafau AM, Tolosa E, DaTSCAN Clinically Uncertain Parkinsonian Syndromes Study Group. Impact of dopamine transporter SPECT using 123I-Ioflupane on diagnosis and management of patients with clinically uncertain Parkinsonian syndromes. *Mov Disord*. 2004;19(10):1175-1182. doi:10.1002/mds.20112
25. Fazio P, Sundgren M, Halldin C, Varrone A, Farde L. Quantitative analysis of 18F-FE-PE2I binding to the dopamine transporter. *J Nucl Med*. 2015;56(5):755-761. doi:10.2967/jnumed.114.152421
26. Pirker W. Correlation of dopamine transporter imaging with parkinsonian motor handicap: how close is it? *Mov Disord*. 2003;18(suppl 7):S43–S51. doi:10.1002/mds.10579
27. Pavese N, Brooks DJ. Imaging neurodegeneration in Parkinson's disease. *Biochim Biophys Acta*. 2009;1792(7):722-729. doi:10.1016/j.bbadis.2008.10.003
28. McKeith IG, Boeve BF, Dickson DW, et al. Diagnosis and management of dementia with Lewy bodies: fourth consensus report of the DLB Consortium. *Neurology*. 2017;89(1):88–100. doi:10.1212/WNL.0000000000004058
29. Treglia G, Cason E, Stefanelli A, et al. Diagnostic performance of myocardial scintigraphy using ^{123}I-MIBG in differential diagnosis between Parkinson's disease and other parkinsonian syndromes: a systematic review and meta-analysis. *Eur J Nucl Med Mol Imaging*. 2012;39(4):623-632. doi:10.1007/s00259-011-2021-1
30. Depierreux F, Parmentier E, Mackels L, et al. Parkinson's disease multimodal imaging: F-DOPA PET, neuromelanin-sensitive and quantitative iron-sensitive MRI. *NPJ Parkinsons Dis*. 2021;7(1):57. doi:10.1038/s41531-021-00199-2
31. Huang C, Tang C, Feigin A, et al. Changes in network activity with the progression of Parkinson's disease. *Brain*. 2007;130(Pt 7):1834-1846. doi:10.1093/brain/awm086
32. Shang S, Li D, Tian Y, et al. Hybrid PET-MRI for early detection of dopaminergic dysfunction and microstructural degradation involved in Parkinson's disease. *Commun Biol*. 2021;4(1):1162. doi:10.1038/s42003-021-02705-x
33. Nordio G, Easmin R, Giacomel A, et al. An automatic analysis framework for FDOPA PET neuroimaging. *J Cereb Blood Flow Metab*. 2023;43(8):1285-1300. doi:10.1177/0271678X231168687
34. Walker Z, Rodda J. Dopaminergic imaging: clinical utility now and in the future. *Int Psychogeriatr*. 2011;23(suppl 2):S32–S40. doi:10.1017/S1041610211000883
35. Brown CA, Karimi MK, Tian L, et al. Validation of midbrain positron emission tomography measures for nigrostriatal neurons in macaques. *Ann Neurol*. 2013;74(4):602-610. doi:10.1002/ana.23939
36. Okamura N, Villemagne VL, Drago J, et al. In vivo measurement of vesicular monoamine transporter type 2 density in Parkinson disease with (18)F-AV-133. *J Nucl Med*. 2010;51(2):223-228. doi:10.2967/jnumed.109.070094
37. Niu J, Zhong Y, Jin C, et al. Positron emission tomography imaging of synaptic dysfunction in Parkinson's Disease. *Neurosci Bull*. 2024;40(6):743-758. doi:10.1007/s12264-024-01188-0
38. Gerfen CR, Young WS 3rd, Surmeier DJ. Segregation of striatal projection neurons based on dopamine receptor expression. In: *The Basal Ganglia V. Advances in Behavioral Biology*, Vol 58. Springer; 2003:3-17.
39. Kaasinen V, Ruottinen HM, Någren K, Lehikoinen P, Oikonen V, Rinne JO. Upregulation of putaminal dopamine D2 receptors in early Parkinson's disease: a comparative PET study with [^{11}C]raclopride and [^{11}C]N-methylspiperone. *J Nucl Med*. 2000;41(1):65-70.
40. Niccolini F, Politis M. A systematic review of lessons learned from PET molecular imaging research in atypical parkinsonism. *Eur J Nucl Med Mol Imaging*. 2016;43(12):2244-2254. doi:10.1007/s00259-016-3464-8
41. Kung HF, Alavi A, Chang W, et al. In vivo SPECT imaging of CNS D-2 dopamine receptors: initial studies with iodine-123-IBZM in humans. *J Nucl Med*. 1990;31(5):573-579.
42. Vandehey NT, Moirano JM, Converse AK, et al. High-affinity dopamine D2/D3 PET radioligands 18F-fallypride and 11C-FLB457: a comparison of kinetics in extrastriatal regions using a multiple-injection protocol. *J Cereb Blood Flow Metab*. 2010;30(5):994-1007. doi:10.1038/jcbfm.2009.270
43. Farde L, Eriksson L, Blomquist G, Halldin C. Kinetic analysis of central [11C]raclopride binding to D2-dopamine receptors studied by PET--a comparison to the equilibrium analysis. *J Cereb Blood Flow Metab*. 1989;9(5):696-708. doi:10.1038/jcbfm.1989.98
44. Holtbernd F, Eidelberg D. The utility of neuroimaging in the differential diagnosis of parkinsonian syndromes. *Semin Neurol*. 2014;34(2):202-209. doi:10.1055/s-0034-1381733
45. Rogeau A, Boer AJ, Guedj E, et al. EANM perspective on clinical PET and SPECT imaging in schizophrenia-spectrum disorders: a systematic review of longitudinal studies. *Eur J Nucl Med Mol Imaging*. 2025;52(3):876-899. doi:10.1007/s00259-024-06987-1
46. Orimo S, Suzuki M, Inaba A, Mizusawa H. ^{123}I-MIBG myocardial scintigraphy for the assessment of cardiac sympathetic denervation in Parkinson's disease. *Prog Neurobiol*. 2012;97(2):154-168. doi:10.1016/j.pneurobio.2011.09.003
47. Matsubara T, Ito K, Kamiya T, et al. Validation of cardiac sympathetic denervation imaging using ^{123}I-MIBG scintigraphy: correlation with pathological α-synuclein deposition in Lewy body disease. *Neurology*. 2022;98(5):e494–e503. doi:10.1212/WNL.0000000000200110
48. Tossici-Bolt L, Hoffmann SM, Kemp PM, Mehta RL, Fleming JS. Quantification of [123I]FP-CIT SPECT brain images: an accurate technique for measurement of the specific binding ratio. *Eur J Nucl Med Mol Imaging*. 2006;33(12):1491-1499. doi:10.1007/s00259-006-0155-x
49. Tossici-Bolt L, Dickson JC, Sera T, et al. [^{123}I]FP-CIT ENC-DAT normal database: the impact of the reconstruction and quantification methods. *EJNMMI Phys*. 2017;4(1):8. doi:10.1186/s40658-017-0175-6

How to cite this article: Pudis M, Rodríguez-Bel L, Cortés-Romera M, Suárez-Piñera M. Dopaminergic pathway imaging: a visual and educational guide. *Neurol Clin Pract*. 2026;16(2):e200599. doi: 10.1212/CPJ.0000000000200599

Downloaded from https://www.neurology.org by Cardiff University (cfu) / Wales on 14 March 2026

Copyright © 2026 American Academy of Neurology. Unauthorized reproduction of this article is prohibited.